



Asymmetrical Septal Hypertrophy diagnosed by MRI: a case report

Mauricio Muleiro Alvarez^{ab1}, Felipe Esparza Salazar^{ab2}, Ángel David Alvarado Torres^{c3}, María Fernanda Osorio Martínez^{c4*}

^aUniversidad Anáhuac México Norte, Centro de Investigación en Ciencias de la Salud (CICSA), Facultad de Ciencias de la Salud, Estado de México, México.

^bCenter of Excellence for Aging and Brain Repair, Morsani College of Medicine, University of South Florida, Tampa, FL, USA.

^cUniversidad Autónoma Metropolitana, Unidad Xochimilco, División de Ciencias Biológicas y de la Salud, Ciudad de México, México.

ID ORCID:

¹<https://orcid.org/0009-0007-6628-4973>, ²<https://orcid.org/0000-0003-1884-5389>, ³<https://orcid.org/0000-0001-7514-8083>,

⁴<https://orcid.org/0009-0005-6785-5139>

<https://doi.org/10.36105/psrua.2024v4n7.05>

ABSTRACT

Asymmetrical septal hypertrophy (ASH) is defined as an increase in ventricular wall thickness greater than 15 mm that is not associated with any other pathology. It is a condition that, in most cases, is caused by a mutation in one of the genes associated with the proteins that form the sarcomere. In this article, we present a case of ASH in a 43-year-old adult. After manifesting tachypnea, dyspnea, and cutaneous pallor, followed by a syncopal episode, the individual seeks medical attention. During the medical evaluation, an electrocardiogram (ECG) is performed, revealing bradycardia at 48 beats per minute and an inverted T wave in leads DI, AVL, V3, V4, V5, and V6. The diagnosis is confirmed through cardiac magnetic resonance imaging, which shows hypertrophic cardiomyopathy with non-obstructive ASH of 27.22 mm. Consequently, it is decided to initiate pharmacological treatment with propranolol, and the patient is still awaiting a surgical timeframe for the placement of an implantable cardioverter-defibrillator (ICD).

Key words: asymmetric septal hypertrophy; sarcomere; sudden death; syncope.

* *Corresponding author:* María Fernanda Osorio Martínez. Universidad Autónoma Metropolitana, Unidad Xochimilco. Address: Calzada del Hueso 1100, Coapa, Villa Quietud, Coyoacán, 04960 Ciudad de México. Tel.: +52 55 1473 3712. Email: ferlunchis@gmail.com

RESUMEN

La hipertrofia septal asimétrica (HSA) se define como un aumento del grosor en la pared ventricular mayor a 15 mm que no está asociado a otra patología. Es una enfermedad que en la mayoría de los casos, tiene como etiología alguna mutación en uno de los genes asociados a las proteínas que forman el sarcómero. En el presente artículo presentamos un caso de HSA en un adulto de 43 años. Después de manifestar taquipnea, disnea y palidez cutánea, seguido de un síncope, acude a revisión. Durante la evaluación médica, se realiza un electrocardiograma (ECG) en el que se observa una bradicardia de 48 latidos por minuto y una onda T invertida en DI, AVL, V3, V4, V5 y V6. El diagnóstico se confirma mediante resonancia magnética cardíaca, que muestra una miocardiopatía hipertrófica con HSA no obstructiva de 27.22 mm. En consecuencia, se decide iniciar un tratamiento farmacológico con propranolol y se encuentra actualmente a la espera de tiempo quirúrgico para la colocación de un desfibrilador cardioversor implantable (DCI).

Palabras clave: hipertrofia septal asimétrica; sarcómero; muerte súbita; síncope.

INTRODUCTION

Cardiomyopathy is defined as a myocardial defect, in which the heart muscle is functionally and structurally abnormal,

in the absence of coronary artery disease, valvular disease, hypertension, and congenital heart disease. There are 3 types of hypertrophic cardiomyopathy; ASH, apical hypertrophy and concentric hypertrophy (Figure 1).¹⁻²

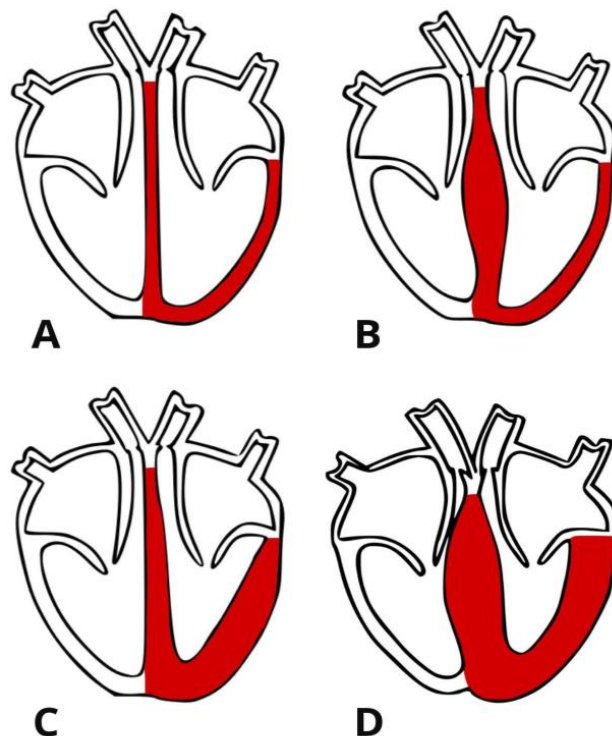


FIGURE 1. Types of hypertrophic cardiomyopathy. This figure shows 3 different types of hypertrophic cardiomyopathy. The first drawing (A) corresponds to a normal heart without thickening in the septum or left ventricle. The second drawing (B) demonstrates ASH, the septum is thickened while the ventricle is not. The third drawing (C) shows an apical hypertrophy where the lowest part of the septum begins to thicken along with the ventricular wall. The last drawing (D) shows a concentric hypertrophy in which both septum and left ventricle are thicker.



ASH is defined as an increase in the thickness of the left ventricular wall (>15 mm thick), which may be accompanied by morphophysiological changes in myocardial cells and/or the mitral valve, not associated with another cause.³ It is considered to have a classic pattern of autosomal dominant inheritance. The etiology in up to 70% of cases is due to a mutation in one of the 14 genes that produce sarcomeric proteins such as troponin I and T, MYH7, or MYBPC3;⁴ up to 10% of cases will be due to other genetic mutations, including diseases like amyloidosis, mitochondrial diseases, nemaline myopathy, Pomp disease, among others.⁵⁻⁶

Depending on the location of the hypertrophy and the thickness of the ventricular wall, the clinical presentation of patients may vary, ranging from asymptomatic individuals to those with diastolic dysfunction, myocardial ischemia, mitral regurgitation, dyspnea, palpitations, asymptomatic murmurs, syncope, stroke secondary to atrial fibrillation, and even sudden death.³

It is important to carry out an appropriate diagnostic approach since it has a worldwide prevalence of 1 in 500 individuals in general and is the number one cause of sudden death in professional athletes and adults under 30 years of age.⁷ In Mexico there are no national statistics. However, at the Ignacio Chávez National Institute of Cardiology, a prevalence of 0.16% was found among the individuals treated there.⁸ Diagnosis is typically conducted through a medical history combined with a physical examination and is confirmed through imaging tests. When there is a suspicion based on the physical examination, an ECG can be requested, as it is the most sensitive routine test, while a Holter electrocardiogram can be requested for risk stratification for sudden death. A 2D echocardiogram is the initial study to evaluate ventricular wall hypertrophy, as well as a magnetic resonance imaging for better visualization.⁹

The treatment will be divided into three categories: pharmacological agents, invasive therapies (such as right ventricular pacing, septal ablation with alcohol and myectomy) and physical conditioning as an adjuvant to modify and address cardiovascular risk factors while reducing morbidity and mortality.¹⁰ Depending on each patient's

characteristics and clinical presentation, they may be candidates for one treatment over the other, with the primary goal being to reduce symptoms and improve the general quality of life.

Sudden mortality events (such as sudden cardiac death) are the principal complications, these occur at an incidence of 0.5-1.5% per year in adults and 2% per year in children and adolescents. However, patients with invasive treatment (as an ICD) have a better long-term prognosis that is similar to their peers in the general population. Showing the importance of a correct diagnosis and an early treatment.⁹

CASE REPORT

A 43-year-old male was admitted to the emergency room of our institution due to syncope while urinating on the previous day, recovering consciousness after 3 minutes. Before the event, he presented tachypnea, dyspnea, and pale integuments. He denies having a similar event before and symptoms at the moment. In his family history these factors are relevant: a mother with systemic hypertension and a father with type 2 diabetes mellitus.

His medical record highlights smoking, stopped 16 years ago (2 cigarettes per day for a period of 3 years), with a smoking index of 0.3. He denies other important antecedents. During the medical examination only a slow heart rate was found, without murmurs or other added phenomena. His vital signs revealed bradycardia of 47 beats per minute and stage 2 hypertension with values of 170/100 mmHg. His Body Mass Index (BMI) was 27.3, which places him in the overweight category.

A 12-lead ECG was taken (Figure 2), which showed sinus bradycardia of 48 beats per minute and T wave inversion in DI, AVL, V3, V4, V5 and V6, demonstrating high lateral subepicardial ischemia. No alterations were found in laboratory studies. The cardiology department then decides his admission to the Coronary Care Unit for study protocol of his sinus bradycardia.



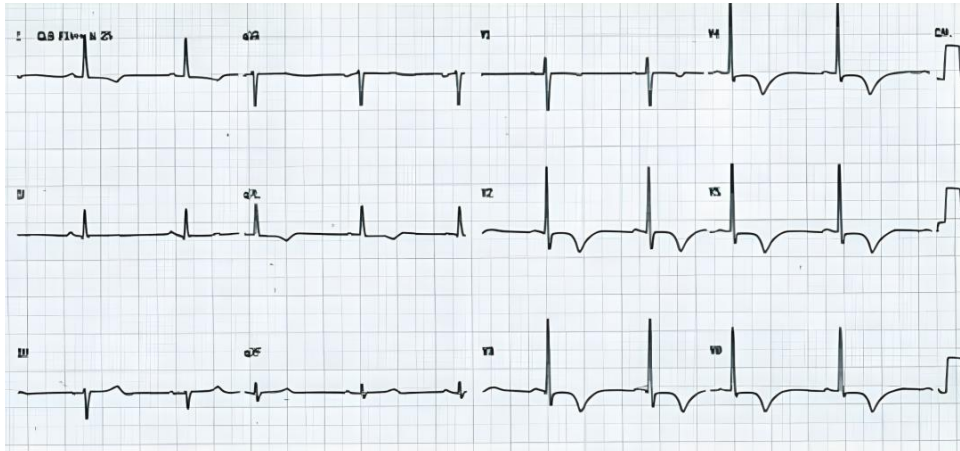


FIGURE 2. 12-lead electrocardiogram performed on the patient. This image corresponds to the ECG performed in the emergency room on the patient. Sinus bradycardia and T wave inversion in DI, AVL, V3, V4, V5 and V6 are shown, demonstrating high lateral subepicardial ischemia.

In the Coronary Care Unit a cardiac MRI was performed (Figure 3), which revealed the presence of hypertrophic cardiomyopathy with nonobstructive ASH of 27.22 mm. Likewise, an echocardiogram was performed, confirming

the diagnosis and showed mild diastolic dysfunction, without pulmonary hypertension and left ventricular ejection fraction (LVEF) 76%.

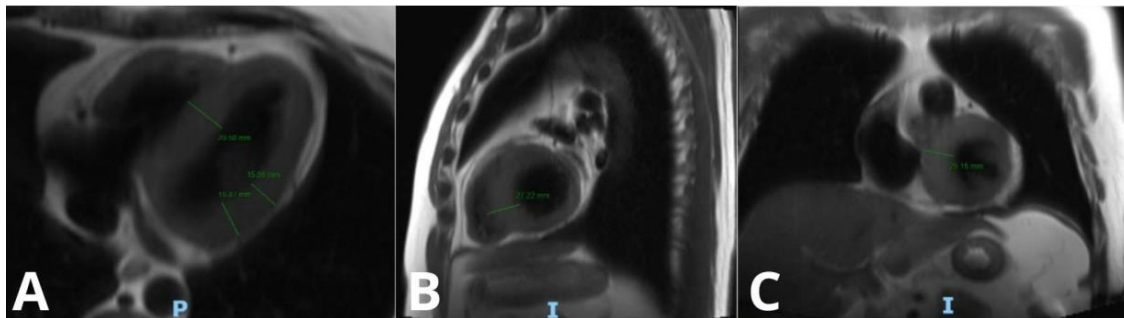


FIGURE 3. Cardiac magnetic resonance with cine sequence with gadolinium. This figure shows three different views of a cardiac magnetic resonance of the patient where cardiomyopathy is seen. In the transversal view (A) it is observed that the left ventricle and the septum are greater than 15 mm and that the septum has a greater measure than the left ventricle. The sagittal plane (B) shows an ASH of 27.22 mm. The coronal view (C) shows mild hypertrophy of the posterior wall of the left ventricle, accompanied by ASH.



Due to his clinical improvement and timely diagnosis, this patient was discharged after 3 days of his admission to the unit with pharmacological treatment based on propranolol at a dose of 4 mg/kg/day and an appointment with the cardiology department to assess the placement of an ICD, which is still pending. Additionally, it was suggested to perform low-intensity aerobic exercise such as walking for 30 minutes 3 to 5 days a week, avoiding fatigue.

DISCUSSION

ASH is characterized by abnormal thickening of the ventricular muscle of the interventricular septal wall. It mainly develops in the initial phase of left ventricular hypertrophy, but is also associated with valvular heart disease, obesity, and congenital heart disease. Therefore, patients develop symptoms of dyspnea and heart failure (orthopnea, angina pectoris, fatigue, syncope and palpitations).¹¹ ASH is typically seen in patients with hypertrophic cardiomyopathy and in patients with high blood pressure.¹² It has an incidence of 1% in the United States, its pathophysiology is due to a relative decrease in the posterior thickness of the left ventricle that causes compensatory hypertrophy of the interventricular septum. Left Ventricular Remodeling Is Associated with Coronary Artery Diseases.¹³

It is associated with sudden death in young athletes due to the presence of ventricular fibrillation and its timely diagnosis is important, making the identification of risk factors and their stratification important. This is achieved with the patients' symptoms and with imaging studies according to the criteria of the American College of Cardiology/American Heart Association (ACC/AHA), however, a large percentage of patients are asymptomatic, and their diagnosis is incidental.³

On physical examination, a harsh midsystolic murmur may be heard over the lower left sternal border that radiates to the apex. The intensity of this murmur increases with the valsalva maneuver. If suspected, it is recommended to perform a 12-lead ECG, reporting growth of the left ventricle, alteration of the ST segment (depression or slight elevation), narrow and deep Q waves from V3 to V6, inversion of T waves in V5 and V6. Another study is the two-dimensional echocardiogram and a cardiovascular magnetic resonance that allows the identification of myocardial fibrosis, the diagnosis is confirmed with hypertrophy of the left ventricle of 15 mm in adults and excluding any other cause.^{3,14-15}

Medical therapy is the first line of treatment for these patients, with the goal of improving symptoms and reducing obstruction. Non-vasodilator beta blockers (Metoprolol, propranolol, bisoprolol and nadolol) are the first line medications; they are safe drugs that improve symptoms, but they improve the obstructive process very little. In case of intolerance, the guidelines recommend the use of non-dihydropyridine calcium channel blockers (diltiazem and verapamil) and in case of intolerance, the use of disopyramide is suggested due to its negative inotropic effect, improving obstruction and symptoms.¹⁶

Another type of treatment is alcohol septal ablation, which is a minimally invasive procedure to correct left ventricular outflow tract obstruction in patients with hypertrophic obstructive cardiomyopathy, which does not improve with medical treatment. This procedure consists of causing a controlled myocardial infarction in the basal portion of the interventricular septum by applying alcohol injection to reduce obstruction and improve the symptoms of the patients. This procedure consists of causing a controlled myocardial infarction in the basal portion of the interventricular septum by applying alcohol injection to reduce obstruction and improve the symptoms of the patients and hemodynamics.¹⁶⁻¹⁷

Septal reduction therapy has been shown to be effective in reducing obstruction and is recommended for use in patients with left ventricular outflow tract obstruction > 50 mmHg, exertional syncope, and severe symptoms. It consists of the reduction of the septum through minimally invasive surgical myomectomy, demonstrating a septal reduction of up to 11 mm and improving the functional class of the patients.¹⁶⁻¹⁷

In recent years, a new drug called Mavacamten has been developed, with its main mechanism of action being a selective inhibitor of β -cardiac myosin ATPase through allosteric binding,¹⁸ leading to a decrease in actin-myosin bridges. This results in Mavacamten's ability to reduce cardiac contractility by decreasing the force generated by sarcomeres. Its usage depends on the left ventricular ejection fraction (LVEF), and discontinuation is advised when it is less than 50%.¹⁹

Despite receiving approval from the Food and Drug Administration (FDA) last year,²⁰ Mavacamten is still under investigation. However, clinical results are promising; in the three studies conducted so far (PIONEER-HCM, EXPLOREER-HCM, and VALOR-HCM), Mavacamten has demonstrated safety and effectiveness in patients with obstructive hypertrophic

cardiomyopathy who were already receiving conventional treatment. It was able to decrease the aortic vestibule, improve left ventricular filling, enhance exercise capacity, and increase quality of life by reducing symptoms, while imaging parameters and biomarkers improved significantly.²¹⁻²³

Despite these promising results, further studies are necessary to clarify all aspects, improve the drug's safety profile, and potentially establish it as a new line of treatment for patients with any type of hypertrophic cardiomyopathy.

The prognosis of patients with ASH depends on the time of diagnosis, the extent of the heart injury, and the comorbidities that the patients present. It is reported that these patients reduce their life expectancy by up to 12 years less compared to a healthy person, because they present a greater risk of developing atrial fibrillation or ventricular arrhythmias, which is why it is required to follow up with an ECG every 1-2 years to prevent complications. Medications and lifestyle changes are the main treatments for ASH. Regarding lifestyle changes, it is recommended to avoid excessive alcohol consumption, avoid dehydration, regular physical activity and reduce the weight of patients.^{3,5,13}

CONCLUSION

Although ASH is a common cardiovascular disease, its clinical variation makes its diagnosis difficult. Likewise, a large percentage of patients remain asymptomatic, causing error in the incidence of the disease. The importance of an early diagnosis lies in the risk of sudden death, so it is important to do a complete history, including family cardiac background and previous episodes of syncope. Physical examination is crucial, highlighting the importance of cardiac auscultation. Complementary tests such as ECG and echocardiogram are essential in patient risk staging and in treatment choice. In our case, we highlight the importance of an early diagnosis and the patient's best treatment based on beta blockers and the implantation of an ICD.

CONFLICT OF INTEREST

The authors declare there are no conflicts of interest.

ACKNOWLEDGEMENTS

I would like to thank everybody involved in the development of this case report for their support and dedication.

FUNDING

The publication was supported by the authors themselves.

REFERENCES

1. Schaufelberger M. Cardiomyopathy and pregnancy. *Heart*. 2019;105(20):1543-1551. <https://pubmed.ncbi.nlm.nih.gov/31308064/>
2. Gowda SN, Ali HJ, Hussain I. Overview of Restrictive Cardiomyopathies. *Methodist Debakey Cardiovasc J*. 2022;18(2):4-16. <https://pubmed.ncbi.nlm.nih.gov/35414858/>
3. Sebastian SA, Panthangi V, Singh K, Rayaroth S, Gupta A, Shantharam D, Rasool BQ, Padda I, Co EL, Johal G. Hypertrophic Cardiomyopathy: Current Treatment and Future Options. *Curr Probl Cardiol*. 2023;48(4):101552. <https://doi.org/10.1016/j.cpcardiol.2022.101552>
4. Biddinger KJ, Jurgens SJ, Maamari D, Gaziano L, Choi SH, Morrill VN, Halford JL, Khera AV, Lubitz SA, Ellinor PT, Aragam KG. Rare and Common Genetic Variation Underlying the Risk of Hypertrophic Cardiomyopathy in a National Biobank. *JAMA Cardiol*. 2022;7(7):715-722. <https://doi.org/10.1001/jamacardio.2022.1061>
5. Ottaviani A, Mansour D, Molinari LV, Galanti K, Mantini C, Khanji MY, Chahal AA, Zimarino M, Renda G, Sciarra L, Pelliccia F, Gallina S, Ricci F. Revisiting Diagnosis and Treatment of Hypertrophic Cardiomyopathy: Current Practice and Novel Perspectives. *J Clin Med*. 2023;12(17):5710. <https://doi.org/10.3390/jcm12175710>
6. Litt MJ, Ali A, Reza N. Familial Hypertrophic Cardiomyopathy: Diagnosis and Management. *Vasc Health Risk Manag*. 2023;19:211-221. <https://doi.org/10.2147/VHRM.S365001>
7. Kochi AN, Vettor G, Dessanai MA, Pizzamiglio F, Tondo C. Sudden cardiac death in athletes: From the basics to the practical work-up. *Medicina*. 2021;57(2):168. <https://doi.org/10.3390/medicina57020168>
8. Márquez MF, Ruíz-Siller TJ, Méndez-Ramos R, Karabut E, Aranda-Fraustro A, Jiménez-Becerra S. Miocardiopatía hipertrófica (MCH). Una revisión histórica y anatómopatológica. *Gac Med Mex*. 2016;152(5):697-702. Available from: <https://www.medigraphic.com/cgi-bin/new/resumen.cgi?IDARTICULO=68916>
9. Veselka J, Anavekar NS, Charron P. Hypertrophic obstructive cardiomyopathy. *Lancet*. 2017;389(10075):1253-1267. [https://doi.org/10.1016/S0140-6736\(16\)31321-6](https://doi.org/10.1016/S0140-6736(16)31321-6)
10. Bayonas-Ruiz A, Muñoz-Franco FM, Sabater-Molina M, Oliva-Sandoval MJ, Gimeno JR, Bonacasa B. Current



- therapies for hypertrophic cardiomyopathy: a systematic review and meta-analysis of the literature. *ESC Heart Fail.* 2023;10(1):8-23. <https://doi.org/10.1002/ehf2.14142>
11. Ozdemir S, Tan YZ, Gazi E. Is the Increased Septal Perfusion the Signal of Asymmetrical Septal Hypertrophy? *World J Nucl Med.* 2016;15(3):184-9. <https://doi.org/10.4103/1450-1147.174706>
 12. Kuznetsov VA, Yaroslavskaya EI, Zyrianov IP, Kolunin GV, Krinochkin DV, Bessonova MI, Bessonov IS. Asymmetric septal hypertrophy in patients with coronary artery disease. *Eur J Echocardiogr.* 2010;11(8):698-702. <https://doi.org/10.1093/ejehocard/jeq046>
 13. Tuset N, Cramariuc D, Rieck AE, Wachtell K, Gerdts E. Asymmetric septal hypertrophy - a marker of hypertension in aortic stenosis (a SEAS substudy). *Blood Press.* 2010;19(3):140-4. <https://doi.org/10.3109/08037051.2010.481816>
 14. Melas M, Beltsios ET, Adamou A, Koumarelas K, McBride KL. Molecular Diagnosis of Hypertrophic Cardiomyopathy (HCM): In the Heart of Cardiac Disease. *J Clin Med.* 2022;12(1):225. <https://doi.org/10.3390/jcm12010225>
 15. Weissler-Snir A, Crean A, Rakowski H. The role of imaging in the diagnosis and management of hypertrophic cardiomyopathy. *Expert Rev Cardiovasc Ther.* 2016;14(1):51-74. <https://doi.org/10.1586/14779072.2016.1113130>
 16. Tschöpe C, Cooper LT, Torre-Amione G, Van Linthout S. Management of Myocarditis-Related Cardiomyopathy in Adults. *Circ Res.* 2019;124(11):1568-1583. <https://doi.org/10.1161/CIRCRESAHA.118.313578>
 17. Gagnano F, Pelliccia F, Guarnaccia N, Niccoli G, De Rosa S, Piccolo R, Moscarella E, Fabris E, Montone RA, Cesaro A, Porto I, Indolfi C, Sinagra G, Perrone Filardi P, Andò G, Calabrò P; Working Group of Interventional Cardiology of the Italian Society of Cardiology. Alcohol Septal Ablation in Patients with Hypertrophic Obstructive Cardiomyopathy: A Contemporary Perspective. *J Clin Med.* 2023;12(8):2810. <https://doi.org/10.3390/jcm12082810>
 18. Grillo MP, Erve JCL, Dick R, Driscoll JP, Haste N, Markova S, Brun P, Carlson TJ, Evanchik M. In vitro and in vivo pharmacokinetic characterization of mavacamten, a first-in-class small molecule allosteric modulator of beta cardiac myosin. *Xenobiotica.* 2019;49(6):718-733. <https://doi.org/10.1080/00498254.2018.1495856>
 19. Dong T, Alencherry B, Ospina S, Desai MY. Review of Mavacamten for Obstructive Hypertrophic Cardiomyopathy and Future Directions. Drug design, development and therapy. 2023;17, 1097-1106. <https://doi.org/10.2147/DDDT.S368590>
 20. Keam SJ. Mavacamten: First Approval. *Drugs.* 2022;82(10), 1127-1135. <https://doi.org/10.1007/s40265-022-01739-7>
 21. Heitner SB, Jacoby D, Lester, SJ, Owens A, Wang A, Zhang D, Lambing J, Lee J, Semigran M, Sehnert AJ. Mavacamten Treatment for Obstructive Hypertrophic Cardiomyopathy: A Clinical Trial. *Annals of internal medicine.* 2019;170(11), 741-748. <https://doi.org/10.7326/M18-3016>
 22. Olivotto I, Oreziak A, Barriales-Villa R, Abraham TP, Masri A, Garcia-Pavia P, Saberi S, Lakdawala NK, Wheeler MT, Owens A, Kubanek M, Wojakowski W, Jensen MK, Gimeno-Blanes J, Afshar K, Myers J, Hegde S M, Solomon SD, Sehnert AJ, Zhang D, Li W, Bhattacharya M, Edelberg JM, Burstein-Waldman C, Lester SJ, Wang A, Ho CY, Jacoby D, EXPLORER-HCM study investigators. Mavacamten for treatment of symptomatic obstructive hypertrophic cardiomyopathy (EXPLORER-HCM): a randomised, double-blind, placebo-controlled, phase 3 trial. *Lancet.* 2020;396(10253):759-769. [https://doi.org/10.1016/S0140-6736\(20\)31792-X](https://doi.org/10.1016/S0140-6736(20)31792-X)
 23. Desai MY, Owens A, Geske JB, Wolski K, Naidu SS, Smedira NG, Cremer PC, Schaff H, McErlean E, Sewell C, Li W, Sterling L, Lampl K, Edelberg JM, Sehnert AJ, Nissen SE. Myosin inhibition in patients with obstructive hypertrophic cardiomyopathy referred for septal reduction therapy. *J Am Coll Cardiol.* 2022;80(2):95-108. <https://doi.org/10.1016/j.jacc.2022.04.048>